

# Ankyloglossia - from histogenesis and parafunctional implications to legal aspects: a bibliographic review

Samuel Saidymon Soares Alves,<sup>1</sup> Luísa Laura Lima Reis,<sup>1</sup> Patrícia Capuço Oliveira,<sup>2</sup> Débora Andalécio Ferreira,<sup>1</sup> Lia Dietrich,<sup>1</sup> Aletheia Moraes Rocha<sup>1</sup>

<sup>1</sup>Department of Dentistry, Faculty of Patos de Minas - FPM, Patos de Minas, MG, Brazil

<sup>2</sup>Department of Dentistry, Brazilian Dental Association - ABO, Uberlândia, MG, Brazil

• **Conflicts of interest:** none declared.

## ABSTRACT

**Objective:** to address the consequences of ankyloglossia when there is no early intervention, in addition to the expected legal implications. **Material and Methods:** this study checked the databases of PubMed, Bireme, Google Scholar, Scielo, Lilacs and Medline. Out of 30 articles found, nine were discarded because they did not identify with the objectives. **Results:** ankyloglossia is a congenital disorder of the lingual frenulum that limits the elevation and protrusion of the tongue due to its short extension and has repercussion throughout the stomatognathic system. It is verified in the literature that the tongue is fully formed in the second month of gestation and that the frenulum is formed after apoptosis of the lingual brake cells and reabsorption of the developing skeletal muscle. Therefore, ankyloglossia is classified in five degrees, according to its mobility, and in four types, according to its thickness and elasticity. The Neonatal Tongue Screening Test is applied in compliance of a law and not performing this test can lead to anatomical and functional consequences for the mother and the baby. The recommended treatment is the frenectomy, although frenotomy and Z-Plasty can be used. **Conclusion:** the conclusion is that the health professionals should not neglect the test, to avoid worsening this condition.

**Keywords:** Ankyloglossia; Stomatognathic system abnormalities; Lingual frenum.

## Introduction

Ankyloglossia, better known by the population as tongue-tie, is a congenital alteration of the lingual frenulum that limits the elevation and protrusion of the tongue due to the short extension of the tongue. This condition is seen at different stages of development, but more commonly in childhood and adolescence. The features of the frenulum, which restrict free movement of the tongue in the oral cavity, are the site of tongue fixation on the oral floor, the size and flexibility of the tissue. It is an anomaly that has repercussion throughout the stomatognathic system, and the changes suffered in chewing, swallowing, occlusion, breathing, suction are highlighted.<sup>1-4</sup>

The literature describes a higher incidence of this condition in males than in females, as published by Baldini *et al.*, the ratio between man:woman is 1.5:1.<sup>5</sup> In the literature, the prevalence of ankyloglossia in the population suffers a variation of 0,1% to 10,7%. If we take into account the age, the newborns vary from 1,72% to 10,7%, while adolescents and adults range from 0,1% to 2,08%.<sup>6</sup> It is believed that this demand is greater than that reported in the literature, since at the time of birth, the condition might be diagnosed immediately by the physician and removed, which is often not reported in the medical records, even though many works, such as that of Coelho *et al.*, highlight the importance of correct and complete filling of medical records.<sup>7</sup>

In 2014, more precisely on June 20th, the Law no. 13.002 known as the Neonatal Tongue Screening Test (NTST) was promulgated, a precursory technique created in Brazil by speech therapist Roberta Martinelli, which consists of diagnosing and treating previously related changes in the devel-

opment of language, which can compromise in their functions. As a justification for institution of the technique are the consequences caused by the change in the lingual frenulum for both the mother and the baby. Therefore, through the application of this law, the birthing centres and hospitals are obliged to perform the evaluation of the lingual frenulum in infants.<sup>8,9</sup>

The NTST is a recommended protocol for patients from 0 to 6 months, period in which the newborn usually does not yet have teeth. This test is divided into three parts, characterized by suction history, nonnutritive and anatomic-functional evaluation.<sup>10</sup>

The present work aims to carry out a narrative literature review about studies that addressed the theme ankyloglossia and its parafunctional consequences, to emphasize the importance of the early identification of this condition in newborns, as well as to clarify on the legal aspects involving the non-compliance of the NTST, which may lead to damages to the mother and the baby.

## Material and Methods

The design of the present study characterizes it as a narrative review of literature, carried out from October 2017 to September 2018; through search in specific database of the health area: Pubmed, Google Scholar, Scielo, Bireme, Lilacs and Medline. The following keywords were used: “test”, “tongue”, “surgery”, “tongue” and “tongue-tie”, and descriptors in health science: “Ankyloglossia”, “Lingual Frenulum”, “Congenital Abnormalities”, “Breastfeeding” and “Stomatognathic System” correlated by “or” and “and”.

We found 30 articles, from which 9 were excluded be-

cause they did not fully fit the objectives of this study. The inclusion criteria were: scientific and review articles that addressed the terms mentioned above, in English and Portuguese languages.

## Results

### Embryogenesis and Anatomic-Histological Features

In the second month of pregnancy, the tongue is already fully formed, but its development begins when the pharyngeal arches are in the midline, which occurs in about the fourth week of the baby's development. From this junction, the lateral lingual protrusions arise with rapid development and join together with the odd tuber forming the anterior two thirds of the tongue. After that, apoptosis of the lingual frenulum cells occurs and with the resorption of the skeletal muscle under development, it causes a retraction in the posterior direction to the apex forming the frenulum.<sup>8,11,12</sup>

The lingual frenulum is a membrane inserted and located medially to the ventral surface of the tongue that connects it to the floor of the mouth, extends from the gingiva to the lingual posterolateral region and recovers the anterior alveolar crest. It consists of a dense and fibrous connective tissue, and often of the upper fibers of the genioglossus muscle. Lingual prolongation and tooth eruption resulting from bone growth and development lead the migration of the lingual frenulum to the center until it establishes in its final position with the eruption of the teeth. It leaves from a more adhered region and goes to another region that has greater mobility.<sup>1,2,5,11,13-15</sup>

### Classification of Ankyloglossia

When alterations of orofacial functions such as chewing, swallowing and speech are present, it is necessary to evaluate the entire anatomy of the oral cavity and the lingual frenulum by the professionals involved. It is not common to follow an exclusive protocol for such evaluation. If changes are observed in the frenulum, the necessary intervention should be indicated, whether surgical or not, but it is known that when alterations in this ana-

tomical structure are detected, the orofacial functions are truly compromised.<sup>14</sup>

Considering the clinical characteristics presented, we can categorize the severity of lingual frenulum hypertrophy in five different degrees. Grade 1 presents the tongue with totally free movement and can reach a higher point. The patient is asked to open his mouth, raise his tongue towards the palate, in which the tongue reaches a perfect degree of verticality.<sup>16</sup>

In grade 2 there is a slight adhesion of the frenulum, presenting almost complete mobility of the tongue. When the patient opens the mouth and tries to bring the tongue to a higher point, there is a slight impediment reaching only three-quarter of the intraoral space, not being able to reach the palate.<sup>16</sup>

In grade 3 there is a hypertrophy with a moderate impairment of lingual mobility, in the examination of the patient the tongue reaches only half of the intra-oral space, generating a bifurcated or heart-shaped appearance due to the tension in the apex caused by restricted lingual mobility.<sup>16</sup>

At grade 4 the frenulum has a very reduced level of mobility, the tongue is lowered, but its base and frenulum are still observed, this degree is considered severe, and is indicated for surgery. By raising the tongue, only one-quarter of the patient's intra-oral space is obtained, presenting reduced movements and thus the bone development and other functions are restricted.<sup>16</sup>

Finally, in grade 5, the patient has a totally impaired lingual mobility, being considered the most severe degree of ankyloglossia, the restriction of movement interferes with the normal development of stomatognathic system structures, directly affecting their functions, thus surgery becomes necessary. Grades 4 and 5 are therefore considered to be severe hypertrophy because they have poor movement power, while grades 1, 2 and 3 are considered normal, and surgery is indicated only if there is an association with another alteration, pathology or disorder (Table 1).<sup>16</sup>

Table 1. Grade of lingual frenulum hypertrophy

Characteristic	Grade 1	Grade 2	Grade 3	Grade 4	Grade 5
Tongue movement	Total movement	Almost total movement	Moderate compromising	Very reduced	Totally impaired
Grade of Intraoral Verticality	Perfect Verticality	$\frac{3}{4}$ of the intraoral space	$\frac{2}{4}$ of the intraoral space	$\frac{1}{4}$ of the intraoral space	Absent Verticality

Source: Amat, 2016<sup>15</sup>

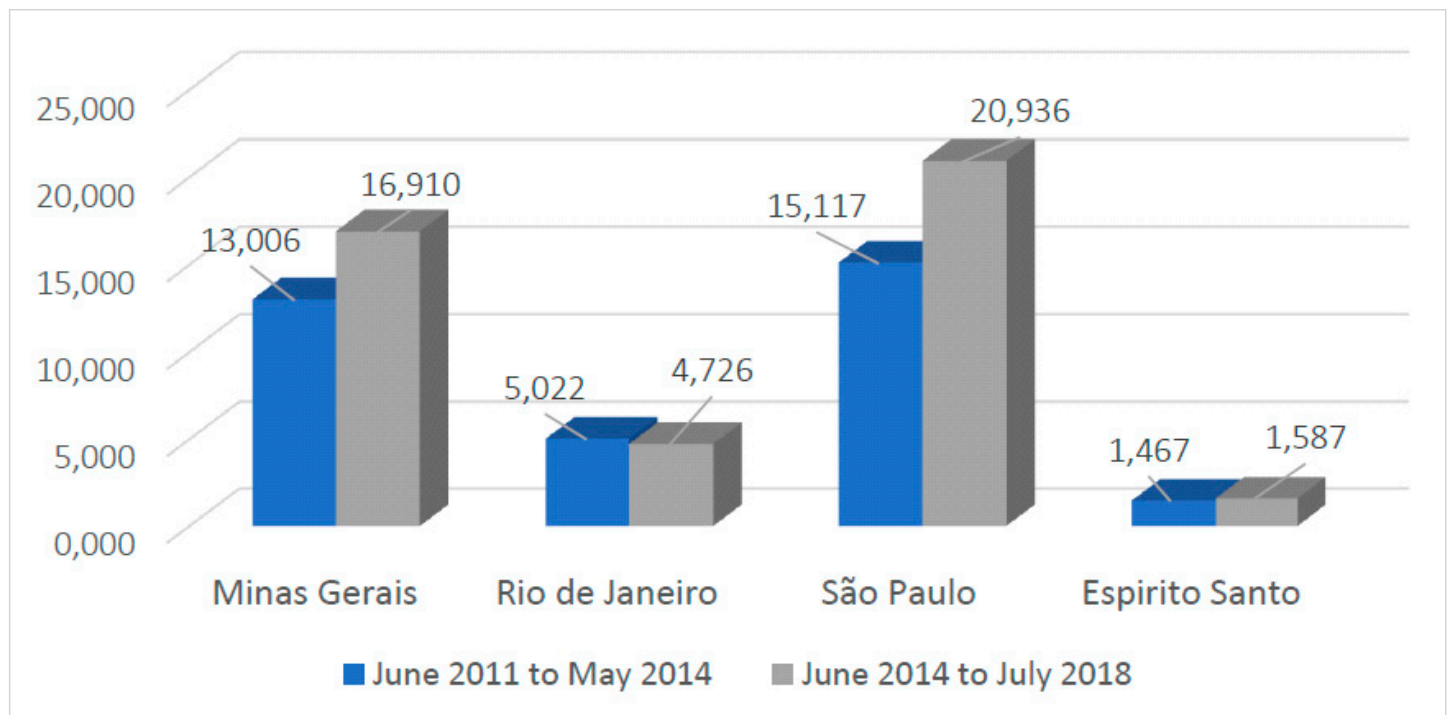
The lingual frenulum is classified based on the type, which is also a characteristic to be evaluated for the diagnosis of ankyloglossia; this classification is named Corryllos. According to it, to be classified as type I, the frenulum must be thin and elastic, the tongue is anchored from the tip to the alveolar crest and is found in the form of a heart. In type II the frenulum is also thin and elastic, however, the tongue is anchored at 2-4 mm from the tip to almost near the alveolar ridge. Type III is characterized by the thick and fibroelastic frenulum, the tongue is anchored from the middle of the tongue to the floor of the mouth. And in type IV it is not possible to visualize the frenulum, only through palpation, and it has a fibrous submucosal anchorage that extends from the base of the tongue to the floor of the mouth.<sup>1</sup>

### The law and the Neonatal Tongue Screening Test

The NTST is a technique developed by the Brazilian speech therapist Roberta Martinelli as an evaluation parameter for newborns' frenulum, and a law was instituted on June 20th, 2014 (Law number 13.002), making the test protocol mandatory in birthing centres and hospitals in Brazil. As previously stated, the test consists of three steps, the first is an anamnesis looking for data that indicate a possible heredity of changes in the frenulum and the behaviour of the baby during breastfeeding. The second part implies a non-nutritive evaluation, taking into

account the suction of the baby according to the protrusion of the tongue and also the production of "cracks" during the suction. In the third stage the anatomical and functional evaluation is carried out, taking into consideration four questions, the first one being the positioning of the lips, followed by the way the tongue is positioned and the shape of the tip of the tongue when the baby is crying, and if it is possible to visualize of the lingual frenulum. Each of the steps has a value in points that at the end of the exam are summed, and if a maximum value of 13 is found, it is a sign of interference of the frenulum in the movements.<sup>9,10,11</sup>

Consulting the database of the Unified Health System - SUS (DATASUS/TABNET), in search of information on the index of tongue frenectomies performed in the southeast region of Brazil, it was observed that there is no separation by the system of the types of frenectomies (lingual and labial), with all of them grouped into a single category. As mentioned, no specific results were found for lingual frenectomy, and it was possible to observe an increase in the procedures performed after the law was implemented, but it is not possible to say precisely that this result was directed to lingual frenectomy, thus further studies are necessary to clarify this data (Figure 1). The search interval was from June 2011 to May 2014 (period prior to the law) and June 2014 to July 2018 (post-law period).<sup>17</sup>



**Figure 1.** Number of frenectomies performed in the Southeast region of Brazil. Intervals from June 2011 to May 2014 and from June 2014 to July 2018

## Consequences of Ankyloglossia for the Mother and the Baby

The most common reason that leads the mother to seek help from a professional regarding ankyloglossia is pain at the time of breastfeeding. It can be considered that lingual frenectomy is responsible for reducing the painful sensation of the mother during the feeding of the child as shown in a study conducted in the United States with women after the age of 18 who sought help in a clinic. With a visual analogue scale ranging from 0 to 10, where 0 means no pain and 10 means extremely severe pain, these women were instructed to assess the pain they felt. The mean value found was 5.6 before the frenectomy was performed, and 2.7 after surgery.<sup>18</sup>

The sucking reflex usually lasts until the baby's first two months of age manifesting since the birth. Breastfeeding is a process that lasts longer and is recommended by WHO (World Health Organization) until the child is 2 years old. For optimal closure between the baby's oral structures and the mother's breast, adequate posture at the time of breast-feeding is required, with the infant having a wide-mouth opening reaching 2 to 3 centimetres from the areola. The baby's tongue needs to reach the areola and lengthen the breast tissue. It is important to emphasize that the tip of the tongue remains in the anterior region, thus allowing the correct sealing of the mouth to the nipple, creating an intra-oral vacuum. Its edges are raised giving it a shell shape, making it easier to obtain milk. In a case of more severe ankyloglossia, the mothers report that the baby cannot reach the areola, only the nipple, therefore there is no sealing and consequently there is no creation of vacuum.<sup>8,11,19</sup>

Ankyloglossia associated with breastfeeding has been debated more frequently, since awareness of its effects, breastfeeding, and increasing initiative to influence breastfeeding may aid in the diagnosis and treatment of this condition. For newborns, breast milk is crucial, which makes breastfeeding extremely relevant to the baby. The movement that the tongue performs is a factor of extreme importance so that the infant obtains the enough quantity of breast milk. Among the problems presented by infants include ineffective sucking, unfavourable weight gain, inadequate milk supply, and the mother may have nipple pain leading to early weaning.<sup>8,13,19,20</sup>

The restricted mobility of the tip of the tongue also causes consequences to the child's communication, being considered an articular disorder. This reduced mobility interferes with the complete closure against the palate and does not allow the creation of the vibration for the correct emission of the sound. The sounds of 's', and 'r' are more commonly affected, but there are also other sounds that

are less influenced, such as 't', 'd', 'l', 'n', 'z' and 'th', which are commonly replaced by other sounds. Early treatment, usually before 5 years of age, provides a better prognosis for speech-related problems. Older patients who were harmed acquiring abnormal speech habits, post-surgical exercises with the tongue and a speech training, both with the assistance of speech-language pathologists, are recommended.<sup>16,21</sup>

## Treatment

Surgical procedures are not mandatory treatments in all cases, some of cases still have an alternative myofunctional therapy that improves the adhesion of the frenulum, obtaining results that provide greater comfort to the mother and baby. If the surgical procedure is necessary, myofunctional therapy is recommended before and after the intervention so that the suction is stimulated and minimize retraction of the scar tissue.<sup>1,20</sup>

When the surgical treatment is necessary, the most commonly used technique is the frenectomy, characterized by incision of the mucous tissue and dissection of the genioglossus muscle. In newborns and/or infants, a frenotomy may also be performed consisting of an incision made in the anteroposterior direction of the frenulum, but there is no tissue removal. Another described technique is called Z-Plasty, which consists of a variation of frenotomy with opposing triangular flaps of 60° alternated and stitched.<sup>11,22,23</sup>

Frenotomy is a simple process where the frenulum is divided into the midline or the underside of the tongue, using sharp pointed scissors. At the time of the intervention, the child is submitted to restraint using a blanket or equivalent equipment if necessary, and if done early in childhood does not require the injection of anesthetic, even though the literature describes that using ophthalmic topical anesthetic during the procedure of neonatal frenotomy may be a good option. Early intervention, usually after the 8th day of birth, results in a greater impact on lactation and weight gain. It is also regularly reported a small bleeding or few complications after performing the technique. On the other hand, a second surgical intervention is required for the entire section of the lingual frenulum, since this technique only softens the consequences caused by ankyloglossia.<sup>1,18,19,24,25</sup>

As previously mentioned, lingual frenectomy consists of sectioning and removing the mucosal tissue from the frenulum. Before the procedure, parents should be advised to avoid breastfeeding for at least one hour. The paediatric package is used to contain and immobilize the child's movements during the surgery, and a submucosal infiltration with anesthetic solution containing vasoconstrictor is

performed. The tongue is gently pulled upwards with the aid of an instrument such as the grooved director with tongue tie, and a horizontal rhomboidal incision is performed, then the genioglossus muscle is dissected with the aid of scissors. After hemostasis, the operated area is stitched, and the mother is recommended to breastfeed immediately. Breast milk contributes to hemostasis and if pain is reported when breastfeeding, immediate relief is noted.<sup>16,25</sup>

## Conclusion

Ankyloglossia is a congenital abnormality that, if undiagnosed and treated early, can lead to mother and baby

consequences in speech development, difficulties in breastfeeding, among other damages. In 2014, the NTST law was instituted, obliging Brazilian birthing centres and hospitals to test newborns in order to minimize these effects. This procedure, when done right after the birth, can be performed by both the dentist and the doctor. The presence of the dental surgeon in the multidisciplinary team of a hospital is a extent field little explored by the professionals, besides being essential to the health of the newborns. It is up to the health professionals involved to be aware of the diagnosis of this anomaly and to execute the NTST in the appropriate time, fulfilling thus the law and avoiding the worsening of symptoms occasioned by this condition.

## References

- Amat EF, Vera TP, Alessi PR, Bueno JN, Padró EF. The prevalence of ankyloglossia in 302 newborns with breastfeeding problems and sucking difficulties in Barcelona: a descriptive study. *Eur. J. Paediatr. Dent.* 2017;18(4):319-25.
- Brito SF, Marchesan IQ, Bosco CM, Carrilho ACA, Rehder MI. Frênulo Lingual: Classificação e conduta segundo ótica fonoaudiológica, odontológica e otorrinolaringológica. *Rev. CEFAC.* 2008;10(3):343-51.
- Vieira EMM, Salineiro FS, Hespagnol D, Musis CR, Jardim Junior EG. Frequência de anquiloglossia em uma comunidade indígena brasileira. *RGO (Porto Alegre).* 2010;58(2):215-8.
- Silva MC, Costa MLVCM, Nembr K, Marchesan IQ. Frênulo de língua alterado e interferência na mastigação. *Rev. CEFAC.* 2009;11(3):363-9.
- Melo NSFO, Lima AAS, Fernandes A, Silva RPGVC. Anquiloglossia: relato de caso. *RSBO.* 2011;8(1):102-7.
- Devasya A, Sarpangala M. Familial Ankyloglossia -A Rare Report of three Cases in a Family. *J ClinDiagn Res.* 2017;11(2):3-4.
- Coelho CA, Fernandes FP, Dietrich L, Martins VM, Andrade CMO. *Prontuário Odontológico - sua composição, importância clínica, ética e legal: Revisão de literatura.* ROC. 2017;1 Suppl 2:4-16
- Fujinaga CI, Chaves JC, Karkow IK, Klossowski DG, Silva FR, Rodrigues AH. Frênulo lingual e aleitamento materno: estudo descritivo. *Audiol. Commun. Res.* 2017;(22):1-7.
- Medeiros HEGB, Leite CRM, Santos JF, Ribeiro Neto PF, Martinelli RLC, Cavalcanti RVA. Sistema de apoio à decisão na realização e acompanhamento do teste da linguinha. *RBCA.* 2016;8(1):104-13.
- Ripplinger T. Protocolo para avaliação de frênulo lingual na primeira infância [Dissertação]. Pelotas: Universidade Federal de Pelotas; 2017.
- Procopio IMS, Costa VPP, Lia EM. Frenotomia lingual em lactentes. *RFO.* 2017;22(1):114-9.
- Campos B, Susanibar F, Carranza CA, Oliveira NCM. Embriologia do Sistema Estomatognático. In: Susanibar F, Marchesan IQ, Ferreira VJA, Douglas CR, Parra D, Dioses A. *Motricidade Orofacial: fundamentos neuroanatômicos, fisiológicos e linguísticos.* Ribeirão Preto: Book Toy;2015; (1):23-60.
- Araújo TR, Barbosa IS, Nascimento ACC, Oliveira LL, Araújo MAV, Jardim JF. Anquiloglossia: Causas consequências e tratamento. *JOAC.* 2016;2(2):1-6.
- Marchesan IQ, Martinelli RLC, Gusmão RJ. Frênulo lingual: modificações após frenectomia. *J Soc Bras Fonoaudiol.* 2012;24(4):409-12.
- Hiatt JL, Gartner LP. *Anatomia Cabeça & Pescoço.* 4ª ed. Rio de Janeiro: Guanabara Koogan; 2011.
- Amat EF, Vera TP, Amat EF, Bueno JM, Armengol JP, Padró EF. Multidisciplinary management of ankyloglossia in childhood. Treatment of 101 cases. A protocol. *Med Oral Patol Oral Cir Bucal.* 2016;21(1):39-47.
- Portal da Saúde - Ministério da Saúde [Internet] DATASUS/TABNET [accessed in 18 set 2018]. Available at: <http://www2.datasus.gov.br/DATASUS/index.php?area=0202&id=19122&VObj=http://tabnet.datasus.gov.br/cgi/deftohtm.exe?sia/cnv/qa>
- Muldoon K, Gallagher L, McGuinness D, Smith V. Effect of frenotomy on breastfeeding variables in infants with ankyloglossia (tongue-tie): a prospective before and after cohort study. *BMC Pregnancy Childbirth.* 2017;17(1):373.
- Wakhanrittee J, Khorana J, Kiatipunsodsai S. The outcomes of a frenulotomy on breastfeeding infants followed up for 3 months at Thammasat University Hospital. *PediatrSurg Int.* 2016;32(10):945-52.
- Walsh J, Tunkel D. Diagnosis and Treatment of Ankyloglossia in Newborns and Infants. *JAMA.* 2017;(1):1-8.
- Ito Y, Shimizu T, Nakamura T, Takatama C. Effectiveness of tongue-tie division for speech disorder in children. *Nippon shonikagakkai zasshi.* 2015;(57):222-26.
- Yousefi J, Tabrizian Namini F, Raisoldadat SM, Hollis R, Ashkezari A, Meara JG. Tongue-tie Repair: Z-Plasty Vs Simple Release. *Iran J Otorhinolaryngol.* 2015;27(79):127-35.
- Isac C. *Frenectomia - Momento Ideal da Intervenção Cirúrgica [Dissertação].* Almada: Instituto Universitário Egas Moniz; 2018.
- Scherber ACK, Newman J. Office-based frenotomy for ankyloglossia and problematic breastfeeding. *Can. fam. physician.* 2016;62:570-71.
- Silva PI, Vilela JER, Rank RCIC, Rank MS. Frenectomia lingual em bebê: Relato de caso. *Revista Bahiana de Odontologia.* 2016;7(3):220-7.

## Mini Curriculum and Author's Contribution

- Samuel Saidymon Soares Alves - DDS. Contribution: data collection, manuscript writing and review, work supervision. ORCID: 0000-0002-2241-6221
- Luísa Laura Lima Reis - DDS. Contribution: data collection and manuscript writing. ORCID: 0000-0003-3842-7803
- Patrícia Capuço Oliveira - DDS. Contribution: data collection, manuscript writing and critical review. ORCID: 0000-0003-4335-9083
- Débora Andalécio Ferreira - DDS; MSc. Contribution: data collection, manuscript writing and review, work supervision. ORCID: 0000-0002-1243-1874
- Lia Dietrich - DDS; PhD Student. Contribution: data collection, manuscript writing and review, work supervision. ORCID: 0000-0001-7887-8591
- Aletheia Moraes Rocha - DDS; PhD. Contribution: data collection, manuscript writing and review, work supervision. ORCID: 0000-0003-1650-7546

Submitted: 12/14/2018 / Accepted for publication: 01/07/2019

### Corresponding Author

Samuel Saidymon Soares Alves

E-mail: [saidymon@hotmail.com](mailto:saidymon@hotmail.com)

