

# Silhouette technique applied on dental preparation - case report

Paulo Eduardo Gomes de Almeida Campos,<sup>1</sup> João Luiz Portella Duarte,<sup>1</sup> Renato da Silva Fraga,<sup>2</sup> Angela Maria Vidal Moreira,<sup>1</sup> Fábio de Almeida Ribeiro,<sup>1</sup> Luciana Meireles Miragaya,<sup>1</sup> Olivia Albertina da Silva Fraga<sup>1</sup>

<sup>1</sup>Department of Dental Prosthesis, School of Dentistry, Rio de Janeiro State University (Uerj), RJ, Brazil

<sup>2</sup>Department of Specific Formation, School of Dentistry, Fluminense Federal University (UFF), Nova Friburgo, RJ, Brazil

• Conflicts of interest: none declared.

## ABSTRACT

**Objective:** the present study aims to show, through a case report, a wear technique capable to provide a correct full crown preparation. **Case Report:** as the patient's need, tooth 21 was prepared for total crown by means of the silhouette technique, in which the volume of dental wear is guided by the thickness of the drills, as well as by the observation of the half dental profile formed after initial wear. A photographic sequence was performed to allow the understanding of preparation stages and its importance. **Results:** the final preparation presented ideal dimensions, within the proposed treatment. **Conclusion:** this approach allowed the correct orientation of the desired preparation.

**Keywords:** Dental preparation; Silhouette technique; Fixed prosthesis.

## Introduction

The success of fixed dental prostheses is determined by three criteria: treatment longevity, pulp and periodontal health and patient satisfaction.<sup>1</sup> How can a prosthesis presents longevity, if dental preparation is not able to maintain it? What if the wear is excessive and lead to biological damage. In this context, dental preparation should not be started before the professional defines the best treatment plan and knows how to perform it, respecting the fundamental biomechanical principles.<sup>2,3</sup>

The retention of a fixed dental prosthesis basically depends on the contact between the internal surfaces of the restoration and the external surfaces of the prepared tooth.<sup>4,5</sup> Knowing this, all dental preparation techniques will converge to one point in common: to control the direction and amount of dental tissues wear, since all the principles to be fulfilled during dental preparation depend on this.<sup>6</sup> Dental wear should be done selectively, according to the aesthetic and functional needs of the planned restoration.<sup>7</sup> The important preservation of periodontal health is directly related to patient's oral hygiene, as well as to the shape, contour and cervical margin location of prepared tooth. The ideal cervical margin location allows the professional to control all clinical procedures and the maintenance of proper hygiene by the patient.<sup>1,8</sup>

The dental preparation should ensure suitable restorative material thickness, while preserving pulp integrity. This minimum thickness required to make a full crown depends on the restoring material selected. On average, wear with a thickness of 0.5 to 0.7 mm on the buccal surface, 1.5 mm on the lingual surface and 2 mm on the in-

teral surface, are well accepted.<sup>9</sup>

One way to guide a correct dental preparation, concerns to initially prepare only a half of the tooth. In this way, the untouched half is used as a reference to wear amount and direction of the preparation, by the observation of the created profile.<sup>10</sup> That described protocol is called the silhouette technique and was developed by the Prosthodontics Department on Bauru's Dentistry College of São Paulo University. In order to reduce the number of steps and diamond burs used, new techniques and preparation instruments have been studied and proposed over the years, always respecting the biological, mechanical, functional and aesthetic principles.<sup>11</sup> The silhouette technique gives the operator a real idea of the amount of worn tooth, as it initially performs the preparation of the half of the tooth, preserving the other half as a guide.<sup>12</sup>

Another recognized technique of dental preparation was proposed by Inoue & Zanetti as the Reference Technique. On that protocol, the first step is to make the horizontal orientation grooves, that determines the amount of wear and the shape of the final preparation. The authors also developed a special sequential-use kit (Inoue / Zanetti / Feltrin-KG-Sorensen- ref.6727 kit) composed by specific burs that enable the dentist to reach the perfect wear preparation thickness according to the selected crown materials.<sup>13</sup>

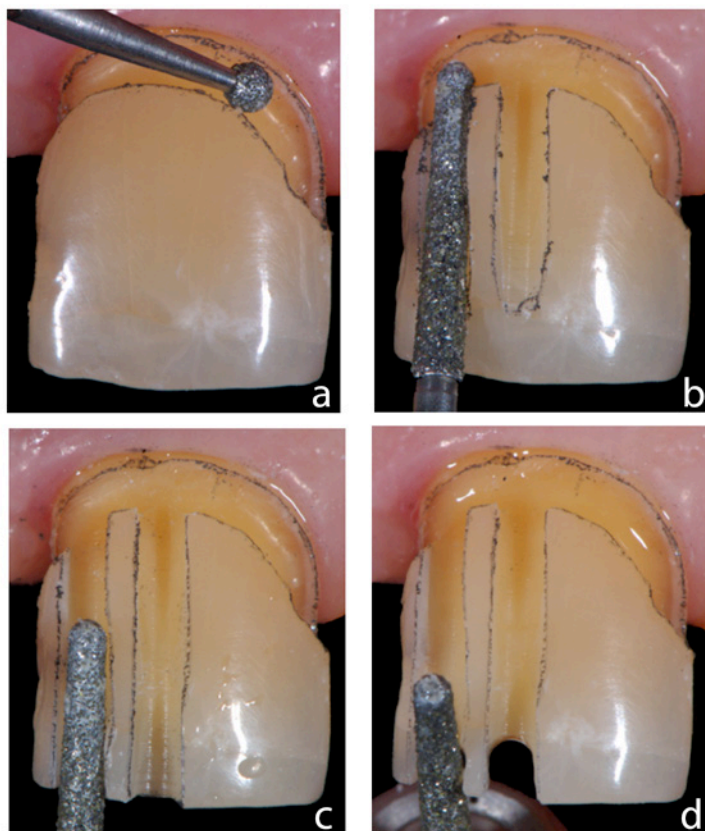
Martignoni *et al.* have stated that all techniques must have a common purpose; the control of depth and direction of removal of dental tissue.<sup>14</sup> The objective of this article is to present a detailed clinical sequence of dental preparation, with photographic illustration, addressing important care on achieving a correct dental wear.

## Report Case

Patient sought dental care at the State University of Rio de Janeiro through the Fixed Prosthesis clinic, reporting as main complaint, functional and aesthetic impairment.

A restorative treatment has been proposed by the preparation of a fixed partial metal-ceramic prosthesis to replace the element 11. To this end, the elements 21 and 12 have been subjected to wear to serve as direct abutments.

The total axial wear of the solid element 21 was chosen, which was performed by the silhouette technique. To this end, the wear was started through the creation of an orientation groove in the cervical portion. A spherical diamond drill with a diameter of 1.4 mm (1014 - KG Sorensen) was used, the wearer extending the vestibular and palatal surfaces until near the proximal contact, in the absence of contact, the groove could extend the proximal faces. The groove depth of approximately 0.7 mm is achieved by introducing the bit at a 45° inclination to the surface to be worn (Figure 1a).

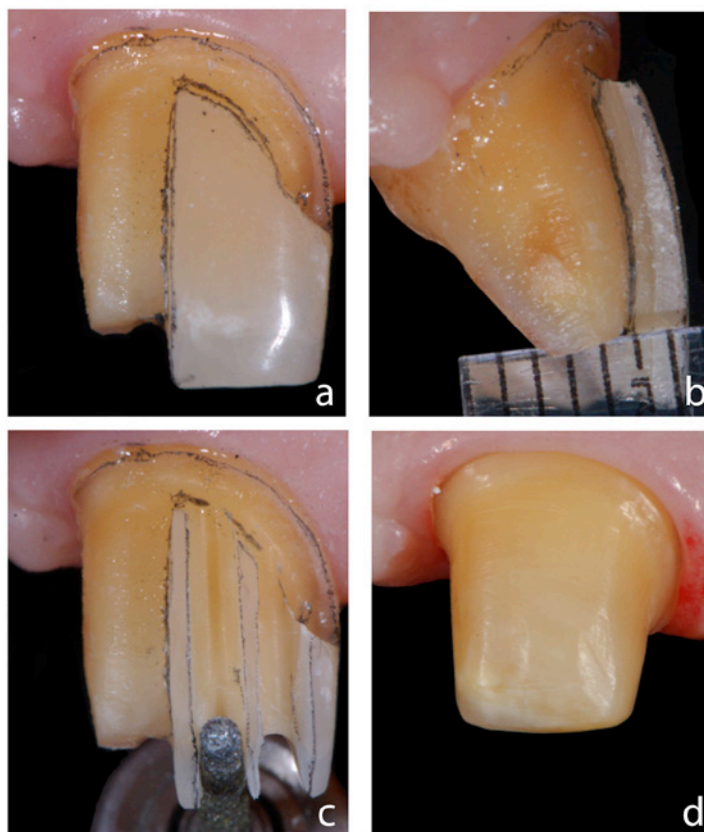


**Figure 1.** Silhouette Technique Applied on Dental Preparation: a) orientation groove in the cervical, b) orientation groove for cervical and middle third vestibular reductions, c) orientation groove for vestibular reduction of the incisal third and c) incisal reduction groove

The metal-ceramic crowns require, on average, 1.5mm of wear on the vestibular face, 1.3mm on the palatal face and 2mm on the incisal portion. Thus, a good way to control wear is through orientation grooves on the buccal, incisal

and palatal surfaces. A diamond drill with rounded end (4138 - KG Sorensen) was used to perform the grooves corresponding to the inclination of the mid-cervical third and the mid-incisal third (Figure 1b and 1c). The incisal grooves are made with the same drill and follow the same direction as the vestibular grooves, being inclined approximately 45° to the long axis of the tooth, facing the lingual surface. Its depth should be around 2mm, corresponding to one and a half times the depth of the drill bit (Figure 1d).

With the same drill, the joints of the vestibular, incisal and palatine grooves are joined, taking care not to lose the relation of pre-established parallelism. The wear of the palatine concavity should be performed with a pear-shaped drill (3168 - KG Sorensen), following the anatomy of the area. After this step, half of the tooth will be prepared, allowing an evaluation of the wear performed (Figure 2a and 2b).



**Figure 2.** Continuation of repair technique applied in dental preparation: a) complete reduction of half the tooth, b) check for wear size, c) orientation groove and d) preparation completed

Once the wear has been analyzed and approved, the preparation of the other half of the dental element begins, following the same care and criteria. (Figure 2c) If there is proximal contact, it must be removed by using a fine diamond drill bit (2200 - KG Sorensen). The proximal scars should terminate at the gingival level and leave the proximal walls parallel to each other. This wear should be performed until a minimum distance of 1mm is reached between the

cervical end of the prepared tooth and the adjacent tooth.

In the case of an aesthetic region, the end of the preparation should be positioned 0.5 mm inside the gingival sulcus, having a chamfer shape (Figure 2d). After finishing the preparation, all walls were finished with multilaminate (583 - KG Sorensen), facilitating future prosthetic steps and contributing to a better adaptation of the restoration.

## Discussion

One of the basic objectives of a preparation technique lies in the simplicity of the procedures.<sup>1</sup> In order for the professional to achieve success in prosthetic restorations, he must follow a judicious protocol in the preparation of dental preparations, since negligence with the technique may lead to failure and consequently will induce the laboratory to make mistake in the making of restoration.<sup>13</sup> The loss of the notion of depth and of the preparation direction during its execution can lead to unnecessary wear and may result in excessive pulp approximation associated with a weakening of the dental structure, whereas inadequate inclinations may result in a significant loss of retention and stability.<sup>1,2,4,10</sup> The more parallel the axial walls of the prepared tooth, the greater the frictional retention of the restoration. However, an exaggerated parallelism may bring undesirable difficulties, especially in the laboratory stages and final cementing.<sup>1,6,7,15</sup> The ideal preparation should have a wear that accompanies the anatomy of the tooth in question. In anterior teeth, a correct incisal wear should be performed in two planes on the vestibular face, thus facilitating aesthetic return and maintaining pulp integrity.<sup>13</sup>

Before initiating any dental wear, planning by means of diagnostic waxing is necessary to determine anatomy and final position of restorations.<sup>1-3,5-7,13</sup> This simulation of the desired end is the safest way to spatially locate the dental preparation.<sup>16</sup> Once the waxing is approved, it is necessary to specify the restorative material to be used, thus determining the minimum thickness to establish adequate restorative patterns.<sup>1,3,7</sup>

Regarding the types of cervical endings, Touati *et al.*<sup>17</sup> recommend for chamfering in metaloceramics the chamfer, in which the amount of dental reduction is on average 1.2 mm from the axial faces and from 1.5 to 2.0 mm on the faces incisal and occlusal, with always rounded and smooth edges. In anterior teeth the preparation should finish intrasulcular so that the metallic strap does not interfere with esthetics.<sup>1</sup> Before determining the position of the end line, the patient's smile line should be evaluated since the less intrasulcular the end of the crown, the better the periodontal health.

There is unanimity among the authors that the major failures leading to prosthetic failure are related mainly to an insufficient reduction of the dental crown and the cervical terminus region leading to an incorrect crown emergence profile in relation to the adjacent periodontal structures, without counting with a weakening of the crown in certain areas and an aesthetic deficiency. They also report that, when the anatomy of the tooth in question is not accompanied, excessive parallelism is created leading to a maladaptation of the future restoration.<sup>1,4,8-10,14</sup>

Carefully following a protocol in the preparation of the preparation guarantees a favorable prognosis in the planning of a total crown. Several techniques are presented with defined protocols, also with suggestion of kits of drills for the accomplishment of the preparations.<sup>12,13</sup> The technique presented in this report followed the basic steps of the silhouette technique, characterized by the creation of vertical orientation grooves and wear of a half of the tooth, which facilitates the visualization of the amount of wear, also results in a uniformity and the more important in the biological economy of dental tissue.<sup>12</sup> The diamond tips were adapted to the reality of the fixed prosthesis discipline of the Faculty of Dentistry of UERJ.

## Conclusion

It can be concluded that this technique allows the operator in performing dental preparations a predictability, guaranteeing to reach the biomechanical principles of prosthetic preparations.

## References

1. Pegoraro LF. Fixed prosthesis: Base for planning. São Paulo: Artes Médicas. 2012
2. Shillingburg HT, Hobo S, Whitsett LD, Jacobi R, Brackett SE. Fundamentals of fixed prosthodontics. 3rd ed. Chicago: Quintessence Publishing; 1997; 119-38.
3. Fradeani M. Aesthetic analysis: a systematic approach to prosthetic treatment. Volume 1. Quintessence; 2006.
4. Ayada MF, Maghrabib AA, Rosenstiel SF. Assessment of convergence angles of tooth preparations for complete crowns among dental students. J Dent. 2005;33(8):633-8.
5. Noonan JE Jr, Goldfogel MH. Convergence of the axial walls of full ve-

neer crown preparations in a dental school environment. J Prosthet Dent. 1991;66(5):706-8.

6. Rosenstiel SF, Land MF, Fujimoto J. Contemporary fixed prosthodontics. 3rd ed. St. Louis: Mosby Inc; 2001;166-201.

7. Mezzomo E. Oral Rehabilitation - For the Clinician. Quintessence. 1994.

8. Pigozzo MN, Laganá DC, Mori M, Gil C, Mantelli AG. Dental preparations with prosthetic purpose: a literature review. Rev Odontol Unid. 2009;21(1):48-55.

9. Ribeiro VAQ et al. Evaluation of the marginal mismatch of copings for total crown metaloceramica in cervical terminus type chamfer and shoulder with bevel 45°. RFO UPP.2010;15(3):281-5.

10. Velasquez-Plata D, Andres CJ. The art of crown preparation: a review of principles. *J Indiana Dent Assoc.* 1996;75(3):6-11.
11. Faria IR, Segalla JMC, Silva RHBT, Pinelli LAP, Reis JMSN. Full Dent Sci. 2011;2(8):396-402.
12. Janson WA *et al.* Preparation of teeth. Silhouette technique (prosthetic purpose). *Apostille of Dentistry Discipline, Faculty of Dentistry of Bauru-USP, 1985.*
13. Farias FAR, Feltrin PP, Zanetti AL, Inoue RT. Tooth preparation to metal-ceramic crowns in anterior tooth using a referencial preparation technique called Inoue & Zanetti. *Rev Gaucha Odontol.* 2011;59(Suppl 0):81-8.
14. Martignoni M, Schonemberger A. Precision in fixed partial prosthesis: clinical and laboratory aspects. São Paulo: Quintessence Books; 1998.
15. Parker MH. Resistance form in tooth preparation. *Dent Clin North Am.* 2004;48(2):387-96.
16. Goodacre CJ. Designing tooth preparations for optimal success. *Dent Clin North Am.* 2004;48(2):359-85.
17. Touati B, Miara P, Nathanson D. Modified ceramic and metal ceramics crowns. São Paulo: Ed.Santos; 2000.

---

---

### Mini Curriculum and Author's Contribution

1. Paulo Eduardo Gomes de Almeida Campos - DDS; PhD. Contribution: effective scientific and intellectual participation for the study; responsible for clinical procedures on the reported case. ORCID: 0000-0003-4598-1706
2. João Luiz Portella Duarte - DDS; PhD. Contribution: effective scientific and intellectual participation for the study; responsible for the literature researches. ORCID: 0000-0002-1000-3163
3. Renato da Silva Fraga - DDS; MsC. Contribution: effective participation for the study, taking and treating the photographs used. ORCID: 0000-0003-2073-0302
4. Angela Maria Vidal Moreira - DDS; PhD. Contribution: effective participation for the study as responsible for bibliographic references. ORCID: 0000-0003-3657-0286
5. Fábio de Almeida Ribeiro - DDS; PhD. Contribution: effective participation for the study on literature review; responsible for clinical case follow-up. ORCID: 0000-0001-9786-4777
6. Luciana Meireles Miragaya - DDS; PhD. Contribution: effective scientific and intellectual participation for the study; critical reviewer; responsible for English text preparation. ORCID: 0000-0003-0864-7004
7. Olivia Albertina da Silva Fraga - DDS; PhD. Contribution: effective scientific and intellectual participation for the study; preparation and drafting of the manuscript; responsible for the final submission. ORCID: 0000-0001-5551-4664

---

---

Submitted: 10/22/2018 / Accepted for publication: 12/06/2018

#### Corresponding Author

**Olivia Albertina da Silva Fraga**

E-mail: oliviasfraga@gmail.com

