

Contact stomatitis to toothpaste: importance of differential diagnosis

Simone Macedo Amaral,¹ Águida Maria Menezes Aguiar Miranda,^{1,2} Juliana de Noronha Santos Netto,^{1,2} Fábio Ramôa Pires^{1,2,3}

¹Brazilian Dental Association – Rio de Janeiro Section (ABO), RJ, Brazil

²School of Dentistry, Estácio de Sá University, RJ, Brazil

³Department of Diagnosis and Therapeutics, School of Dentistry, Rio de Janeiro State University (UERJ), RJ, Brazil

• **Conflicts of interest:** none declared.

ABSTRACT

Objective: the aim of the present study is to report four cases of toothpaste-related contact stomatitis focusing on their clinical presentation and the importance of differential diagnosis with other reactive, inflammatory and potentially malignant disorders of the oral cavity. **Case report:** the four cases affected adult females and presented as multifocal whitish and/or erythematous patches and plaques affecting the tongue, floor of mouth, and labial mucosa, showing mild burning sensation, and lasting 7 to 15 days. All patients reported starting the use of new toothpastes few days before the onset of the symptoms and all lesions disappeared in 5 to 7 days after suspension of its use. **Conclusion:** contact stomatitis to toothpastes should be considered in the differential diagnosis of oral white and red patches and plaques, and detailed clinical history is essential for prompt and correct final diagnosis. As the use of new oral rinses, toothpastes and other oral hygiene products is increasing, clinicians should be aware of the possibility of oral local reactions associated with their use.

Keywords: Contact stomatitis; Oral; Adverse reactions; Toothpaste.

Introduction

Contact stomatitis is a local reaction to direct contact of an agent with the mucosal surface.¹ These reactions are associated with contact of the trigger substance with the surface of the epithelial cells leading to alteration in some antigens inducing the formation of local non-circulating antibodies that produce an antigen-antibody local reaction.²⁻⁴ Several oral hygiene and cosmetic products have been associated with oral contact stomatitis, including toothpastes, dental floss, denture cleansers, mouthwashes, lipsticks, soaps, liquid medicines, pharmaceutical throat medications, and balms.⁴⁻⁷ Recently, numerous cases have been attributed to tartar-control toothpastes containing large quantities of pyrophosphates.⁴

There is few documented data regarding oral adverse soft tissue reactions associated with toothpastes and they are generally considered low-risk products. However, based on the cases reported in the literature, it can be speculated that contact cheilitis and/or stomatitis associated with these products is underestimated. For example, the frequency of positive patch tests to toothpaste-containing substances in patients with cheilitis was almost 10 times higher than controls in one study.⁸ Additionally, as the number of new oral hygiene products is increasing, it seems likely that the frequency of these reactions will increase as well.^{9,10} The aim of the present study is to report four additional cases of oral contact stomatitis to toothpaste focusing on their differential diagnosis.

Case Report

Case 1 - A 48-year-old female was referred for consultation presenting several painful and burning whitish desquamative plaques on the floor of the mouth lasting 15 days (Figure 1). Medical history was non contributory. Patient reported that she had started the use of a different toothpaste just before the onset of the lesions. Clinical provisional diagnosis included contact stomatitis to toothpaste, oral burn, pseudomembranous candidosis and leukoplakia. The patient was oriented to stop the use of the toothpaste and the lesions disappeared in 5 days, confirming the diagnosis of contact stomatitis. The patient remains in clinical follow-up for 24 months with no signs of recurrence.

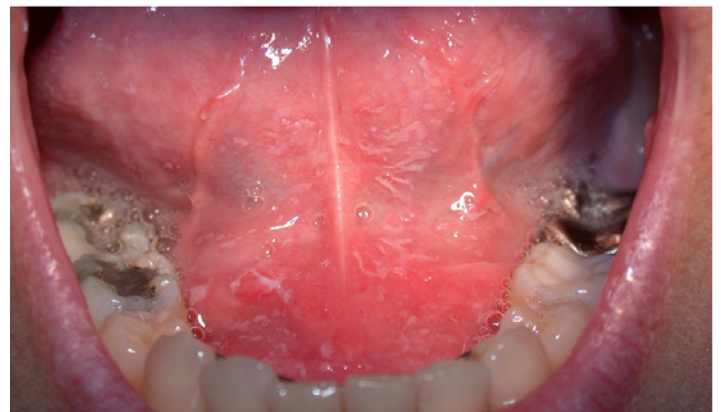

Figure 1. Case 1. Whitish desquamative plaques on the floor of mouth

Case 2 – A 67-year-old female was referred for evaluation of several painless reddish plaques on the ventral tongue and lower labial mucosa (Figure 2 A and B). The patient reported that the lesions have appeared 7 days before and also that she had started to use a different toothpaste 10 days before. Her medical history was non contributory. Clinical provisional diagnosis included contact stomatitis to toothpaste, erythematous candidosis and erythroplakia. Interruption of the use of the toothpaste resulted in remission of the lesions in 7 days (Figure 2 C and D). The patient remains in clinical follow-up for 18 months with no signs of recurrence.

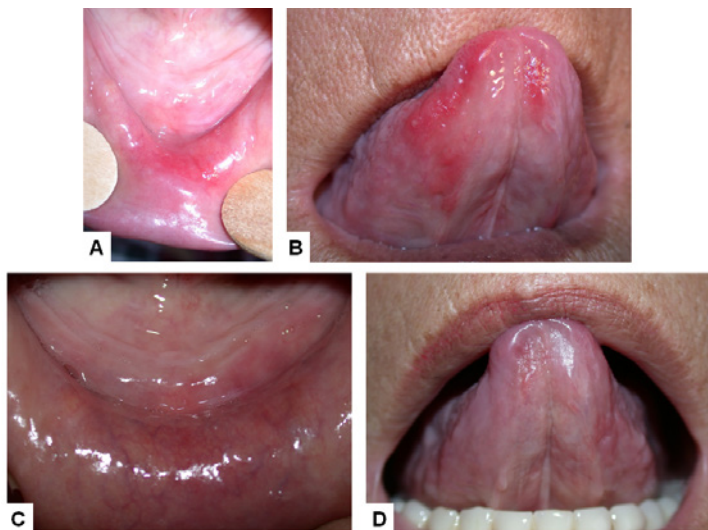


Figure 2. A. Reddish plaque on the lower labial mucosa. B. Reddish plaques on the ventral tongue. Complete remission of the lesions on the lower labial mucosa (C) and ventral tongue (D) in 7 days

Case 3 – A 22-year-old female was referred for evaluation of moderate painful reddish plaques on her lower labial mucosa lasting 2 days (Figure 3). The patient reported that burning sensation and red lesions have appeared after she started the use of a different toothpaste. Her medical history was non contributory. Clinical provisional diagnosis was contact stomatitis to toothpaste and interruption of its use resulted in remission of the lesions in 5 days.

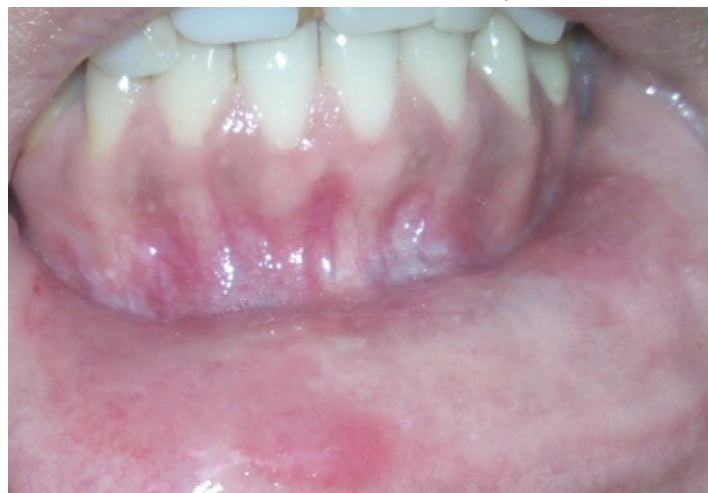

Figure 3. Case 3 – Reddish plaques on the lower labial mucosa

Case 4 – A 56-year-old female was referred for evaluation of several painful reddish plaques, vesicles, and aphthae-like lesions on her lower labial mucosa lasting 7 days (Figure 4). Medical history revealed controlled arterial hypertension. The patient reported starting the use of a different toothpaste 3 weeks before the onset of the lesions. Clinical provisional diagnosis included contact stomatitis to toothpaste, aphthous ulcers, erosive lichen planus, mucous membrane pemphigoid, and pemphigus vulgaris. Interruption of the use of the toothpaste resulted in remission of the lesions in 7 days.

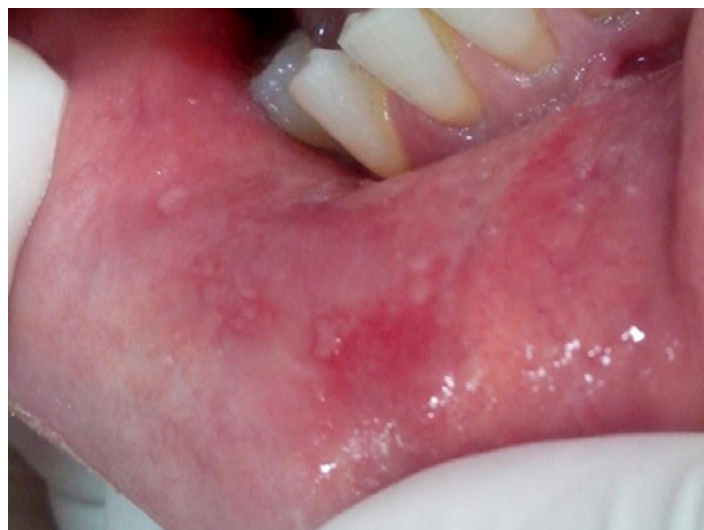

Figure 4. Case 4 – Reddish plaque and vesicles on the lower labial mucosa

Discussion

It has been shown that some toothpastes, especially the anti-tartar and bleaching products, can induce local contact stomatitis in the oral mucosa and perioral skin.^{4,6} The clinical manifestations can include oral mucosal erythema, localized edematous changes, desquamation, formation of vesicles, localized whitish areas due to hyperkeratosis, glossitis, gingivitis, cheilitis and perioral dermatitis and can be accompanied by burning sensation, pain and taste alterations.^{1,2,9-13} As the clinical picture is unspecific, differential diagnosis can include, apart from contact and allergic reactions, chemical burns, inflammatory and immunologically-mediated mucocutaneous disorders (e.g. erythema multiforme), infections (mostly acute candidosis), but also potentially malignant disorders.^{1-3,14} In the diagnostic process the exact time elapse from the first manifestation, symptoms, previous episodes and history of contact with any new substance (mostly food, drugs and hygiene products) are essential to rule out some of the previously listed provisional diagnosis. Once a suspected trigger is identified, suspension of its use (e.g. toothpaste) is almost always sufficient for confirmatory diagnosis, as shown by the present cases.^{2,9,15} If no resolution

is seen, a cytologic smear or incisional biopsy, when applicable, may be indicated to rule out other possible diagnosis.⁹ Besides that, it is essential to call attention that some sporadic cases can be associated with IgE-mediated anaphylaxis and also produce systemic allergic signs and symptoms.¹⁶

The toothpaste components most associated with oral local contact reactions are sodium lauryl sulfate, pyrophosphate and hexametaphosphate, and some aromatizing substances, such as cinnamic aldehyde, cinnamon oil, mint and pepper.^{6,17,18} Toothpaste flavors, which are fragrance mixtures commonly containing oils of peppermint and spearmint, carvone and anethole, seem to represent the most common toothpaste allergens.^{4,5,7,10,13,19-21} Other allergens in toothpaste flavors include menthol and dipentene^{5,7} and less commonly associated substances include chlorhexidine, stannous fluoride, triclosan, propolis and hydrogen peroxide.^{1,2,22-25} Whitening and anti-tartar toothpastes are more associated with oral reactions due to the constant presence of irritant agents, especially peroxyde, pyrophosphate and hexametaphosphate, substances responsible for improving teeth cleanliness and whiteness.^{9,26-28} Since pyrophosphate has a bitter taste, the amount of flavoring substances tends to be higher in toothpastes for tartar control and this increase may contribute to this irritant effect in some individuals.^{9,26} Toothpastes contain synthetic detergents, called

surfactants, and these substances not only provide effervescent action but also help to distribute the toothpaste in the oral cavity.²⁹ One of these detergents, sodium lauryl sulfate, has been associated with an increased risk of inducing mucosal irritation, skin permeability and gingival blood flow.^{9,13,30,31} Another surfactant that has been associated to toothpaste-associated cheilitis is cocamidopropyl betaine.³² The toothpastes associated with the present reported cases contained stannous fluoride, sodium hexametaphosphate, hydrated silica, glycerin, saccharin, zinc lactate, trisodium phosphate, sodium lauryl sulfate, sodium glutamate, carrageenan, titanium dioxide and cellulose gum. Some of these substances have been previously associated with local oral contact reactions, but it is difficult to evaluate the involvement of any specific substance in the present cases as the patients were not submitted to any contact or allergic probes.

Conclusion

Contact stomatitis to toothpastes should be considered in the differential diagnosis of oral white and red macules, patches and plaques, and careful anamnesis is essential for prompt correct final diagnosis. As the use of new oral rinses, toothpastes and other oral hygiene products is increasing, clinicians should be aware of the possibility of oral local reactions associated with their use.

References

- Farina R, Andreotti C. Chronic relapsing allergic contact cheilitis from a toothpaste. A case report. *Minerva Stomatol.* 2007;56(3):145-52.
- Amaral SM, Miranda AMMA, Netto JNS, Pires FR. Drug-induced oral reactions: relevant aspects to stomatology. *Rev Bras Odontol.* 2009;66(1):41-53.
- Zirwas MJ, Otto S. Toothpaste allergy diagnosis and management. *J. Clin. Aesthet. Dermatol.* 2010;3(5):42-7.
- Francalanci S, Sertoli A, Giorgini S, Pigatto P, Santucci B, Valsecchi R. Multicentre study of allergic contact cheilitis from toothpastes. *Contact Dermatitis* 2000;43(4):216-22.
- Poon TS, Freeman S. Cheilitis caused by contact allergy to anethole in spearmint flavoured toothpaste. *Australas. J. Dermatol.* 2006;47(4):300-1.
- Sainio EL, Kanerva L. Contact allergens in toothpastes and a review of their hypersensitivity. *Contact Dermatitis* 1995;33(2):100-5.
- Bourgeois P, Goossens A. Allergic contact cheilitis caused by menthol in toothpaste and throat medication: a case report. *Contact Dermatitis* 2016;75(2):113-5.
- Lavy Y, Slodownik D, Trattner A, Ingber A. Toothpaste allergy as a cause of cheilitis in Israeli patients. *Dermatitis* 2009;20(2):95-8.
- Bhattacharyya I. Case of the Month. Toothpaste-related oral lesions. *Today's FDA* 2009;21(10):11-3.
- Van Baelen A, Kerre S, Goossens A. Allergic contact cheilitis and hand dermatitis caused by a toothpaste. *Contact Dermatitis* 2016;74(3):187-9.
- Kuttan NA, Narayana N, Moghadam BK. Desquamative stomatitis associated with routine use of oral health care products. *Gen. Dent.* 200149(6):596-602.
- Lawrence LM, Farquharson A, Brown RS, Vatanka HO. Oral tissue irritants in toothpaste: a case report. *J. Clin. Pediatr. Dent.* 2013;38(1):75-8.
- Franks A. Contact allergy to anethole in toothpaste associated with loss of taste. *Contact Dermatitis* 1998;38(6):354.
- Holmes G, Freeman S. Cheilitis caused by contact urticaria to mint flavoured toothpaste. *Australas. J. Dermatol.* 2001;42(1):43-5.
- Kowitz G, Jacobson J, Meng Z, Lucatorto F. The effects of tartar-control toothpaste on the oral soft tissues. *Oral Surg. Oral Med. Oral Pathol.* 1990;70(4):529-36.
- Paiva M, Piedade S, Gaspar A. Toothpaste-induced anaphylaxis caused by mint (*Mentha*) allergy. *Allergy* 2010;65(9):1201-2.
- Gerlach R. Comparative intraoral tolerance of sodium hexametaphosphate and pyrophosphate antitartar dentifrices. *J. Clin. Dent.* 2002;13(1):29-32.
- Panasoff J. Cheilitis caused by to mint-containing toothpastes. *Contact Dermatitis* 2016;75(4):260.
- Hansson C, Bergendorff O, Wallengren J. Contact urticaria caused by carvone in toothpaste. *Contact Dermatitis* 2011;65(6):362-4.
- Corazza M, Levratti A, Virgili A. Allergic contact cheilitis due to carvone in toothpastes. *Contact Dermatitis* 2002;46(6):366-7.
- Worm M, Jeep S, Sterry W, Zuberbier T. Perioral contact dermatitis caused by L-carvone in toothpaste. *Contact Dermatitis* 1998;38(6):338.
- Brailo V, Boras VV, Alajbeg I, Juras V. Delayed contact sensitivity on the lips and oral mucosa due to propolis - case report. *Med. Oral Patol. Oral Cir. Bucal* 2006;11(4):e303-4.
- Enamandram M, Das S, Chaney KS. Cheilitis and urticaria associated with stannous fluoride in toothpaste. *J. Am. Acad. Dermatol.* 2014;71(3):e75-6.
- Ozkaya E, Bozkurt PK. An unusual case of triclosan-induced immunological contact urticaria. *Contact Dermatitis* 2013;68(2):121-3.
- Robertshaw H, Leppard B. Contact dermatitis to triclosan in toothpaste. *Contact Dermatitis* 2007;57(6):383-4.
- DeLattre VF. Factors contributing to adverse soft tissue reactions due to the use of tartar control toothpastes: report of a case and literature review. *J. Periodontol.* 1999;70(7):803-7.
- Davies R, Scully C, Preston AJ. Dentifrices - an update. *Med. Oral Patol. Oral Cir. Bucal* 2010;15(6):e976-82.
- Joiner A. Whitening toothpastes: a review of the literature. *J. Dent.* 2010;38(Suppl 2):e17-24.
- Hansson C, Bergendorff O, Wallengren J. Contact urticaria caused by carvone in toothpaste. *Contact Dermatitis* 2011;65(6):362-4.
- Ersay M, Tanalp J, Ozel E, Cengizlier R, Soyman M. The allergy of toothpaste: a case report. *Allergol. Immunopathol. (Madr)* 2008;36(6):368-70.
- Lee AY, Yoo SH, Oh JG, Kim YG. Two cases of allergic contact cheilitis from sodium lauryl sulfate in toothpaste. *Contact Dermatitis* 2000;42(2):111.
- Agar N, Freeman S. Cheilitis caused by contact allergy to cocamidopropyl betaine in '2-in-1 toothpaste and mouthwash'. *Australas. J. Dermatol.* 2005;46(1):15-7.

Mini Curriculum and Author's Contribution

1. Simone Macedo Amaral – DDS; MSc. Contribution: data acquisition, data interpretation; preparation and draft of the manuscript; critical review and final approval. ORCID: 0000-0003-3511-668X
 2. Águida Maria Menezes Aguiar Miranda – DDS; MSc. Contribution: effective scientific and intellectual participation for the study; data acquisition, data interpretation; preparation and draft of the manuscript; critical review and final approval. ORCID: 0000-0002-5958-9054
 3. Juliana de Noronha Santos Netto – DDS; MSc. Contribution: effective scientific and intellectual participation for the study; data acquisition, data interpretation; preparation and draft of the manuscript; critical review and final approval. 0000-0001-6099-3823
 4. Fábio Ramôa Pires – DDS; PhD. Contribution: effective scientific and intellectual participation for the study; data acquisition, data interpretation; preparation and draft of the manuscript; critical review and final approval. ORCID: 0000-0003-0317-8878
-

Submitted: 11/18/2018 / Accepted for publication: 12/29/2018

Corresponding Author

Fábio Ramôa Pires

E-mail: ramoafop@yahoo.com