

Oral mucosal avaluation through clinical and cytopathological exams to identify candidiasis

Nathália de Almeida Freire,¹ Juliana Tristão Werneck,² Eliane Pedra Dias,³ Adrianna Milagres,³ Arley Silva Júnior³

¹Department of Diagnosis and Therapeutic, School of Dentistry, State University of Rio de Janeiro (UERJ), Rio de Janeiro, RJ, Brazil

²Department of Specific Formation, School of Dentistry, Fluminense Federal University (UFF), Nova Friburgo, RJ, Brazil

³Postgraduate Program in Pathology, Medical School, Fluminense Federal University (UFF), Niterói, RJ, Brasil

• **Conflicts of interest:** none declared.

ABSTRACT

Objective: this study aimed to evaluate individuals with lesions that have been clinically diagnosed as oral candidiasis but have not been confirmed by cytopathological exam. In addition, individuals with oral exam not indicative of candidiasis but with positive cytopathology for candidiasis were also evaluated. **Material and method:** the demographic and clinical profiles of the sample were described to determine whether there was a correlation between clinical exam indicative of candidiasis and the cytopathological exam results. A total of 99 participants were selected and all of them underwent anamnesis, intraoral exam, and photographic documentation. Scrap were collected for cytological evaluation. **Results:** of the 99 individuals analyzed, 78 (78.8%) were female and 45 (45.5%) were white. The mean age was 62.7 years. Cytopathological results confirmed candidiasis in 43 of the 61 individuals (70.5%) in the group clinically diagnosed with candidiasis and in 10 of the 38 individuals (28.9%) in the group clinically not diagnosed with candidiasis. Candidiasis was not identified in the cytopathological exam of 18 of the 61 individuals (29.5%) in the group clinically diagnosed with candidiasis and in 28 of the 38 individuals (71.1%) in the group clinically not diagnosed with candidiasis. **Conclusion:** in most cases, there was an agreement between the clinical and cytopathological exams; however, the discordant results demonstrated the importance of the cytopathological exam in the identification or not of candidiasis.

Keywords: Oral candidiasis; Oral moniliasis; Candida; Cytopathological exam; Oral exam.

Introduction

Candidiasis is a fungal infection caused by species of the genus *Candida* (*Candida* spp.), which contains approximately 200 species and it presents with several varied clinical manifestations.^{1,2}

The microorganism has been described to be present in the microflora of the skin, the genitourinary and gastrointestinal tracts of healthy individuals.⁴ It is present on the oral mucosa of an estimated 45%–65% of healthy children and 30%–50% of healthy adults in its asymptomatic form and usually commensally.^{3,4, 5, 6, 7}

The commensal organism can become pathogenic when the regular balance of the microbiota or immune system is disturbed.⁸ The presence of the fungus is not enough to cause the disease, and predisposing factors are required. These include salivary changes, drug therapies, endocrine disorders, immunological disorders, malignant diseases, and removable denture.^{9,10}

The most commonly found species is *Candida albicans*, isolated in approximately 80% of all oral lesions, due to its adhesion properties and its pathogenic features. It is described as a dimorphic fungus, manifesting itself both as yeast and as hyphae, depending on its environment. Hyphae have invasive properties, which promote tissue invasion, damage, and its pathogenic phenotype. Other species can also be found, such as *C. dubliniensis*, *C. glabrata*, *C. krusei*, *C. kefyr*, *C. parapsilosis*, *C. stellatoidea*, and *C. tropicalis*.⁵

In the oral mucosa, microorganisms are usually found on the tongue, palate, and buccal mucosa, and have also been found in periodontal pockets.¹¹

Candidiasis can be diagnosed by clinical exam of the oral mucosa and confirmed by cytopathological exam, culture, or biopsy.⁵ Culture is a method frequently used to identify *Candida* spp.; however, fungal growth does not necessarily imply disease occurrence.^{12, 13, 14, 15,16}

Cytopathology is a non-invasive method well-tolerated by patients and although it depends on the expertise of a cytopathologist evaluation, it is a reliable tool for diagnosis because in addition to identifying pathogenic forms of *Candida* spp., it allows evaluation of inflammatory changes associated with candidiasis.^{17,18,19}

Erythematous and leukoplakia clinical findings are usually treated as oral candidiasis, even before suitable laboratory exam for diagnosis. The indiscriminate use of antifungals can lead to a growth of other microorganisms in the flora. Thus, the association of clinical exam with cytopathological exam provides an accurate diagnosis and consequently a correct treatment approach. Accurate management of oral candidiasis requires the identification of the risk factors and the elimination or treatment of the related causes.⁵ Topical antifungals, such as nystatin, clotrimazole, and miconazole, have been recommended. The systemic treatment includes fluconazole, itraconazole, ketoconazole, and amphotericin B.⁵

The objectives of this study were to analyze individuals

with lesions that were clinically diagnosed as oral candidiasis but cytopathological exam was not diagnosis as candidiasis. In addition, individuals without clinical diagnosis of candidiasis but with a positive cytopathological exam for candidiasis, indicating the presence of subclinical lesions or false negative clinical exam were also evaluated.

Material and Methods

This study was approved by the research ethics committee (CAAE n°. 0356.0.258.000-11). The sample comprised of individuals referred to the Oral Diagnosis Clinic of the Graduate Program in Pathology (PPG-P) at the Hospital Universitário Antônio Pedro of the Fluminense Federal University (HUAP/UFF), in the year 2016. All individuals were submitted to anamnesis, intraoral exam, photographic documentation, and cytopathological exam. A spreadsheet was created specifically for this study using Microsoft Office Excel 2007, containing the following data: name, age, gender, skin color, underlying diseases, medications being used, removable denture use, tobacco and alcohol use, presence of oral lesions, symptoms, location and pattern of the lesions, and clinical diagnosis. The inclusion criteria were the following: individuals aged ≥ 18 who agreed to participate of the study. Exclusion criteria were the following: individuals with intellectual disabilities or who could not cooperate and those who failed to comply with the clinic protocol, individuals with insufficient or inappropriate material for the cytopathological exam analysis, with incomplete data for the study analysis, or with inadequate photographic documentation. Those who met the criteria for the study were invited to participate and were asked to sign an informed consent form.

Intraoral exam data were selected in order to classify clinically the diagnosis of candidiasis in the participants. The criteria of Neville *et al* and Armstrong *et al* were used in the study.^{21,22}

Scraping for the cytopathological exam was performed in all individuals, both in lesions identified during intraoral exam as well as in the whole oral mucosa, even in the absence of clinical changes. The samples were sent to the Oral Cytopathology Department of the Pathologic Anatomy Service at HUAP/UFF, and the exam results were recorded in the study spreadsheet.

Participants with clinical diagnosis of candidiasis were grouped and their profiles were analyzed individually and intragroup. In the second step, clinical candidiasis (CC) and without clinical candidiasis (WCC) groups were compared. Cytopathological diagnosis of each participant was distributed into these two groups and diagnostic agreement was analyzed.

The statistical program SPSS (Statistical Package for the Social Sciences, version 20.0) was used for data analysis.

Results

We analyzed 99 participants, of which 78.8% were female and 45.5% were white. Their mean age was 62.7 years (range 21–88 years). Most participants were non-alcohol and non-tobacco user. The most common systemic diseases observed were hypertension (60.6%), diabetes mellitus (20.2%), and gastrointestinal disorders (34.34%). (Table 1)

Table 1. Demographic profile of 99 analyzed individuals

Data	Result	n (%)
Gender	Female	78 (78.8%)
	Male	21 (21.2%)
Skin color	White	45 (45.5%)
	Brown	35 (35.3%)
	Black	19 (19.2%)
Tobacco use	Yes	11 (11.1%)
	No	58 (58.6%)
	Ex-user	30 (30.3%)
Alcohol use	Yes	18 (18.2%)
	No	67 (67.7%)
	Ex-user	14 (14.1%)
Age	21-30	4 (4.04%)
	31-40	2 (2.02%)
	41-50	6 (6.06%)
	51-60	30 (30.3%)
	61-70	36 (36.36%)
	71- 80	12 (12.12%)
	81 and older	9 (9.09%)
Systemic diseases	Hypertension	60 (60.6%)
	Diabetes mellitus	20 (20.2%)
	Gastrointestinal disorders	34 (34.34%)

Of the 99 participants analyzed, 61 (61.6%) were clinically diagnosed with candidiasis comprising CC group, whereas the remaining 38 (38.4%) participants constituted WCC group.

Erythematous candidiasis was clinically diagnosed in 48 individuals (78.7%), pseudomembranous candidiasis in eight (13.1%), angular cheilitis in five (8.2%), and hyperplastic candidiasis in four individuals (6.5%).

The most common location of erythematous lesions was the palate ($n = 38$), followed by the tongue ($n = 28$), lower alveolar ridge ($n = 6$), left buccal mucosa, and upper alveolar ridge ($n = 4$). (Figure 1)

The distribution between the groups regarding denture use revealed that a great majority of the CC group used complete upper dentures ($n = 33$; 54%) and 26 (43%) used partial lower dentures. In the WCC group, most individuals did not use upper dentures (17, 44.7%) or lower dentures (16, 42.1%).

The cytopathological exam results showed features of

candidiasis in 43 of the 61 individuals (70.5%) in the CC group and in 10 of the 38 individuals (28.9%) in the WCC group. No cytopathological features compatible with candidiasis were observed in 18 of the 61 individuals (29.5%) in the CC group and in 28 of the 38 individuals (71.1%) in the WCC group.

Figure 2 shows the distribution of agreement and disagreement between clinical and cytopathological exams.

It was observed individuals with clinical diagnosis of candidiasis, showing clinical changes indicative of candidiasis but cytopathological exam did not show any features compatible with the disease (CC CyNC). They were thus considered false positives. (Figure 3 and 4) Similarly, there were individuals without any clinical signs of candidiasis but with a cytopathological diagnosis indicative of the presence of candidiasis (WCC CyC). (Figure 5 and 6)

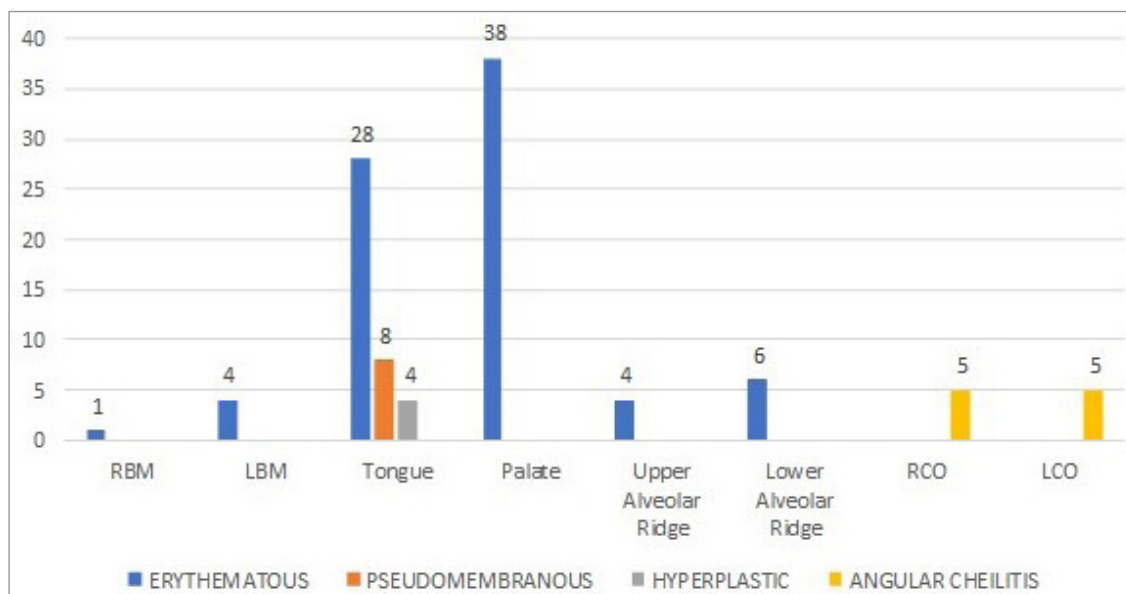


Figure 1. Distribution of the most common location of clinically diagnosed candidiasis lesions (Source: Oral Diagnosis Clinic, Hospital Universitário Antônio Pedro, Universidade Federal Fluminense).

Abbreviations: RBM = Right Buccal Mucosa, LBM = Left Buccal Mucosa, RCO = Right Commissure, LCO = Left Commissure

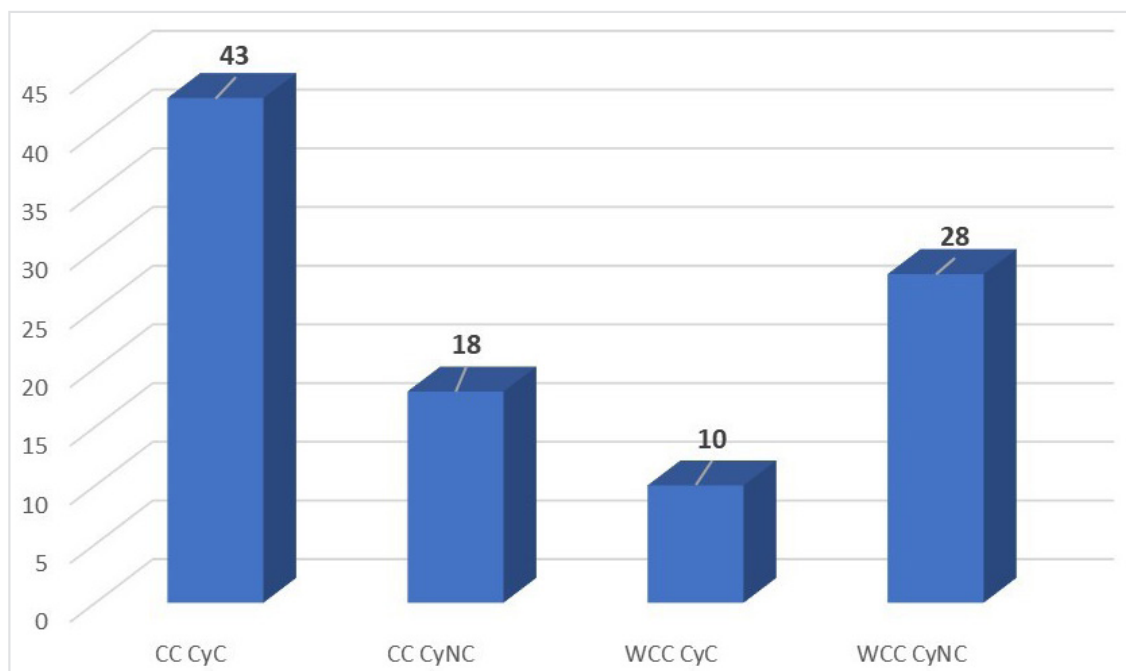


Figure 2. Distribution of candidiasis diagnosis considering clinical and cytopathological exams (Source: Oral Diagnosis Clinic, Hospital Universitário Antônio Pedro, Universidade Federal Fluminense).

Abbreviations: CC CyC = Clinically diagnosed with candidiasis and cytopathological features compatible with candidiasis, CC CyNC = Clinically diagnosed with candidiasis and cytopathological features not compatible with candidiasis, WCC CyC = Without clinical diagnosed of candidiasis and cytopathological features compatible with candidiasis, WCC CyNC = Without clinical diagnosed of candidiasis and cytopathological features not compatible with candidiasis

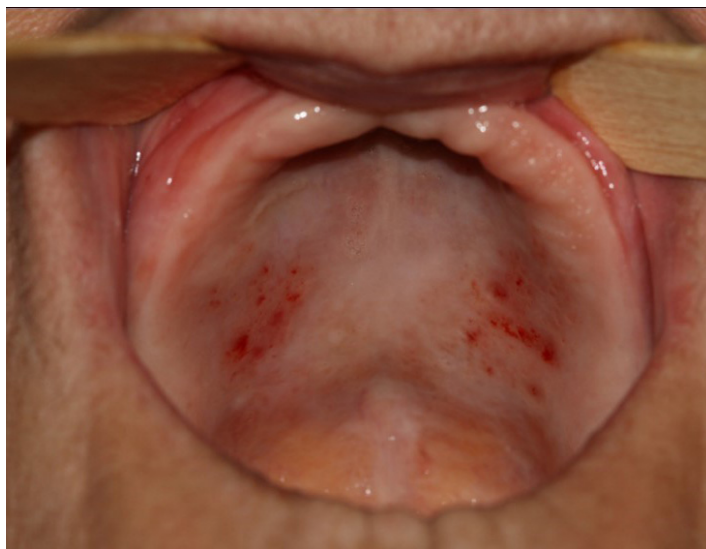

Figure 3. Clinical diagnosis of candidiasis and without cytopathological diagnosis of candidiasis (CC CyNC). Erythematous lesion on palate showed clinical changes indicative of candidiasis but did not show any features compatible with the disease on cytopathological exam (Source: Oral Diagnosis Clinic, Hospital Universitário Antônio Pedro, Universidade Federal Fluminense).

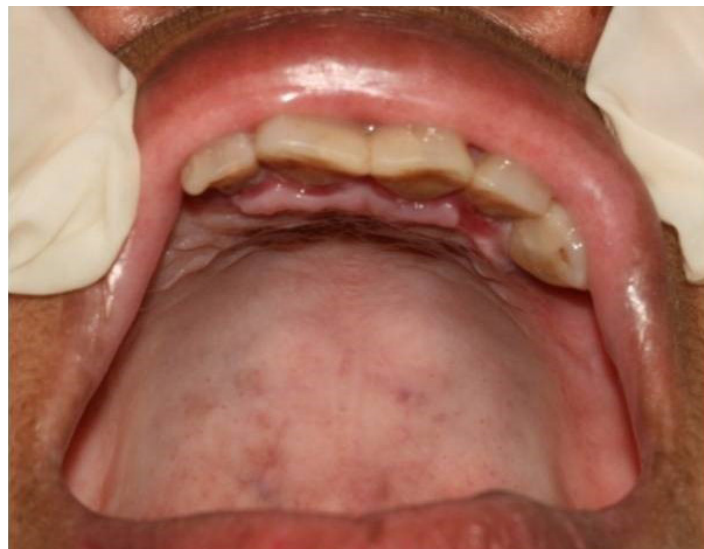

Figure 5. Without any clinical signs of candidiasis but with a cytopathological diagnosis of candidiasis (WCC CyC). Palate without clinical changes indicative of candidiasis but cytopathological exam positive for candidiasis (Source: Oral Diagnosis Clinic, Hospital Universitário Antônio Pedro, Universidade Federal Fluminense).

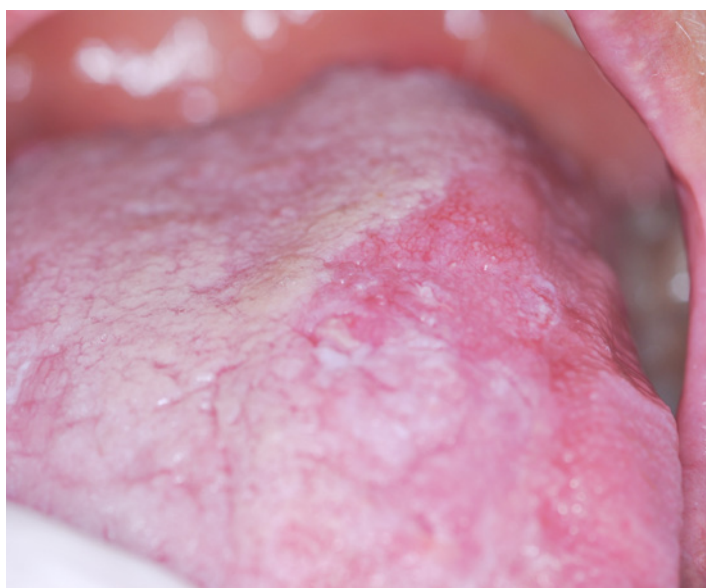

Figure 4. Clinical diagnosis of candidiasis and without cytopathological diagnosis of candidiasis (CC CyNC). Erythematous area on the tongue showed clinical changes indicative of candidiasis but with features compatible with squamous cell carcinoma on cytopathological exam (Source: Oral Diagnosis Clinic, Hospital Universitário Antônio Pedro, Universidade Federal Fluminense).

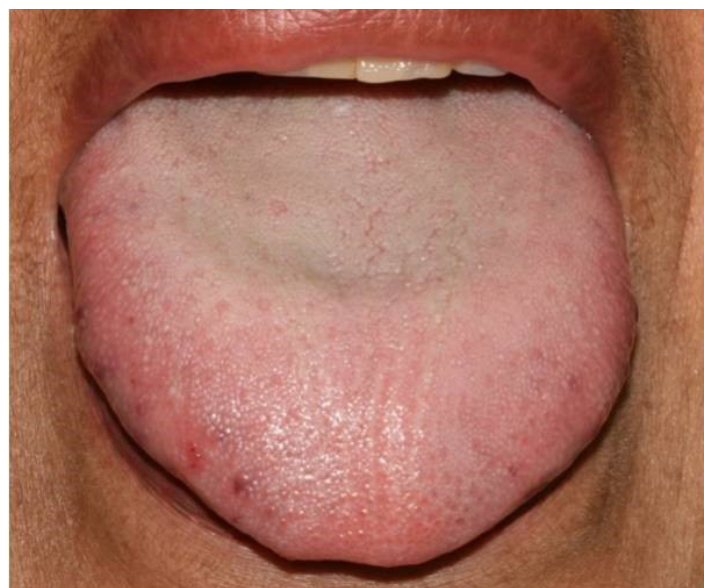

Figure 6. Without any clinical signs of candidiasis but with a cytopathological diagnosis of candidiasis (WCC CyC). Tongue without clinical changes indicative of candidiasis but cytopathological exam positive for candidiasis (Source: Oral Diagnosis Clinic, Hospital Universitário Antônio Pedro, Universidade Federal Fluminense).

Discussion

We observed that most participants were female (78.8%). Many studies have demonstrated this predominance, including the one conducted by Davies *et al* (2008),²⁴ in which 252 of the 390 participants (65%) were females. We believe that this predominance can be explained by the fact that more females look for the HUAP oral diagnosis clinic than males and they are generally more concerned about their health.

It has been reported that candidiasis mostly affects individuals in early age or in advanced age. In some studies, the patients' age ranged from 13 to 87 years, with a mean of 56.1 years.²⁰ We did not include children in the study and the minimum age of 18 years was an inclusion criterion. We observed a mean age of 62.7 years, which is in agreement with the results reported in literature.

Tobacco and alcohol consumption are described as risk factors for candidiasis. They contribute to the changes of the oral environment, and when consumed in excess, they may be associated with poor oral hygiene.² Despite this association, most participants in our study either did not drink alcohol (67.7%) or were former drinkers (14.1%) and were either non-smokers (58.6%) or former smokers (30.3%). These data are quite interesting because they show that, despite being considered as predisposing factors, they are not determinants. In a study by Lopez *et al* (2002), only 23% of participants with candidiasis were smokers, which is in accordance with our findings.

Some systemic diseases have been related to the development of candidiasis, and it is known that at least three factors can determine the clinical evidence of infection: the immune status of the host, the environment of the oral mucosa, and the strain of *C. albicans*.²¹ In the present study, the most common systemic diseases affecting the participants were hypertension, diabetes mellitus, and gastrointestinal disorders. Diabetes changes the host immune response and thus predisposes the individual to candidiasis. According to Akpan & Morgan (2002), diabetes is considered a predisposing systemic factor and it was found in 20.2% of the participants in our study.⁹ In addition, the medications used to control these diseases, such as diuretics for hypertension and antibiotics for certain gastrointestinal conditions, may cause an imbalance in the oral mucosal environment and thus lead to candidiasis development. In a study by Lopez *et al* (2002), hypertension was the most frequently detected medical condition, as was observed in this study.

Erythematous candidiasis was the form most frequently detected in clinical exam in this study (78.7%), and the most common locations were the palate and the tongue (62.3%). In

a study by Davies *et al* (2008),²⁴ the most common locations for pseudomembranous candidiasis (the most frequent form of the disease) were the buccal mucosa (48%), tongue (44%), and hard palate (8%), and acute erythematous candidiasis was mostly detected on the tongue (57%), buccal mucosa (29%), and hard palate (14%). This difference from our data may be explained by the fact that most of our participants were older adults and used dentures, which are more associated with erythematous candidiasis located on the palate. Furthermore, in Davies *et al* (2008) study it was consisted of cancer patients, who exhibited changes that could be related to the underlying disease and its treatments, which may justify the higher frequency of the pseudomembranous form and the different location prevalence.²⁴ Denture-related stomatitis, which can be related to candidiasis, can be observed on the palate of denture users. Older adults may also have other conditions, such as hyposalivation, which we could not analyze but may predispose to erythematous candidiasis on the tongue. Erythematous candidiasis is the most common form of *Candida* infection, even though it is clinically neglected.²¹ Erythema is harder to identify, especially when the manifestation is milder, but a thorough examination of the oral mucosa was conducted by a stomatologist in our study, which probably explains why changes in the oral mucosa were identified more often and better described.

The relationship between denture-related stomatitis and the clinical manifestation of candidiasis is still the topic of many discussions. Some authors consider it important to clarify if *Candida* infection is present or not, because the erythema may be related to bacterial infection, poor hygiene, poorly-made dentures that could cause pressure on the palate mucosa, inadequate polymerization, and allergy to components of the denture.²¹ We know that all these factors can cause palatal erythema with the development of petechiae. This clinical presentation can lead the professional to misdiagnose candidiasis.

The comparison between users and non-users of complete and partial upper dentures within the CC group showed that 54% and 42.6% of the denture users exhibited lesions on the palate and on the tongue, respectively. According to Scalercio *et al* (2007), users of dentures are more likely to have clinical candidiasis.¹⁹ Akpan & Morgan (2002) stated that dentures are a local predisposing factor for candidiasis.⁹ However, we found that 13 (39.4%) of the 33 erythematous clinical changes on the palate that had been diagnosed as candidiasis on intraoral exam had no confirmation in the cytopathological exam, and were considered as cases of denture-related stomatitis unrelated to candidiasis. Therefore, these data reinforce the importance of confirming that

erythematous lesions clinically suggestive of candidiasis, especially those related to the use of dentures, are in fact candidiasis. Cytopathological exam proved to be an extremely useful and efficient tool because it is non-invasive, easy to collect sample, is well-tolerated by patients, and has well-established cytopathological criteria for the diagnosis of candidiasis. Treatment approach to rule out candidiasis should not be an option considering its disadvantages as the possibility of antimicrobial resistance.

Of the 28 erythematous lesions on the tongue that were clinically diagnosed as candidiasis, six (21.4%) were not confirmed by cytopathological exam. Four lesions were subsequently diagnosed as atrophic tongue, probably associated with another condition such as iron deficiency or even geographic tongue. One other case was diagnosed as hyperpigmentation of the tongue, confirmed by histopathological exam. In the latter case, the cytopathological exam revealed cellular changes, resulting in the diagnosis of squamous cell carcinoma, which led to subsequent biopsy that confirmed the cytopathological diagnosis. Cases like this one show that when cytopathological exam does not confirm candidiasis, it is possible to use other tools for diagnostic confirmation.

Cytopathological exam allowed the diagnosis of a squamous cell carcinoma after clinical suspicion of candidiasis, which was confirmed by histopathological exam and the correct referral of the patient for treatment was achieved. We consider these findings extremely important because they highlight the fact that clinical exam, like any exam or laboratory approach, has its limitations, and that a clinical diagnosis should be confirmed whenever possible and indicated. Bernstein & Miller (1978) emphasized the importance of cytopathological exam and described it is a powerful instrument for detecting early malignant lesions, precursors of cancer, and some infections (such as fungal infections).²³ Erythroplakia and leukoplakia can be an example of these lesions and may also be misdiagnosed as candidiasis. Cytopathological exam also has its limitations and, similar to any other exam, depends on adequate sample collection and an experienced cytopathologist for correct interpretation and results. We recommend it as a method of choice for routine stomatology practice.

Of the 99 individuals analyzed, 43 had candidiasis which was clinically and cytopathologically confirmed showing an agreement between both methods (CC CyC). This agreement was also found in 28 individuals who did not exhibit clinical characteristics of candidiasis and also had negative cytopathological exam results (WCC CyNC). A great majority of studies, including that by Davies *et al* (2008), use

culture, which is considered the gold standard for the diagnosis of candidiasis, as their method of choice.²⁴ However, culture has some limitations that should be taken into consideration. Its result might be positive regardless of whether *Candida* is present as yeast, pseudohyphae, or hyphae. The yeast can colonize the oral mucosa of individuals without causing the disease, so these individuals may have positive results without necessarily having candidiasis. Thus, a positive culture result does not guarantee the presence of candidiasis. On the other hand, cytopathological exam has well established diagnostic criteria for candidiasis, such as the presence of grouped keratinized epithelial cells, which often have and overlap presentation, inflammatory alterations in association with neutrophils and hyphae or pseudohyphae of *Candida* species.²⁴ This makes cytopathology the best method of choice for the diagnosis of candidiasis.

With regard to the cases in which a disagreement between the clinical and cytopathological exam was observed, 18 of the 99 individuals (18.2%) had a clinical diagnosis of candidiasis and negative in cytopathology, whereas 10 (10.1%) had no clinical features of candidiasis but had positive cytopathology for candidiasis. As described earlier, a majority of cases with a clinical diagnosis of candidiasis and negative cytopathology were related to erythema, especially cases of denture-related stomatitis, which are erroneously interpreted as candidiasis. Scalercio *et al* (2007) also observed individuals diagnosed with candidiasis but they actually had denture-related stomatitis unrelated to *Candida*.¹⁹ It is important to highlight that approximately 10% of our cases had no clinically detected changes in the oral mucosa but had candidiasis diagnosed by cytopathological exam, thereby being considered as cases of subclinical candidiasis. The detection of subclinical candidiasis provides the professional with an opportunity to select the best treatment and management of patients and to understand their progress. When simultaneous to a systemic disease, immunosuppression, or changes in the oral environment, this subclinical form may progress to a clinical and more severe manifestation.

Conclusion

We conclude the erythematous lesions should be carefully evaluated because squamous cell carcinoma may exhibit clinical features similar to erythematous candidiasis. Cytopathological exam proved to be an important tool in the diagnosis of candidiasis as well as in the identification of other diseases, such as squamous cell carcinoma. We propose that this method should be used in the routine of stomatology practice.

References

1. Cannon RD, Holmes AR, Mason AB, *et al.* Oral Candida: clearance, colonization or candidiasis? *J. Dent. Res.* 1995; 74 (5):1152-61.
2. Oliveira JC. Tópicos em Micologia Médica. 3ª ed. Rio de Janeiro: Control-Lab Editora, 2012.
3. Edmond MB *et al.* Nosocomial bloodstream infections in United States hospitals: A three-year analysis. *Clin. Infect. Dis.* 1999; 29:239-244.
4. Kao AS, *et al.* The epidemiology of candidemia in two United States cities: Results of a population-based active surveillance. *Clin. Infect. Dis.* 1999; 29:1164-1170.
5. Millsop JW, Fazel N. Oral candidiasis. *Clin Dermatol.* 2016; 34(4):487-94.
6. Patil S, Rao RS, Majumdar BANIL, S. Clinical Appearance of Oral Candida Infection and Therapeutic Strategies. *Front Microbiol.* 2015; 17;6:1391.
7. Wisplinghoff H, Ebberts J, Geurtz L, Stefanik D, *et al.* Nosocomial bloodstream infections due to *Candida* spp. in the USA: species distribution, clinical features and antifungal susceptibilities. *Int J Antimicrob Agents.* 2013-2014; Jan;43(1):7881.
8. Barbedo LS, Sgarbi DBG. Candidíase. *J Bras Doenças Sex Transm.* 2010; 22(1):22-38.
9. Akpan A, Morgan R. Oral Candidiasis. *Postgrad Med J.* 2002; 78:455-459.
10. Sharon V, Fazel N. Oral candidiasis and angular cheilitis. *Dermatologic Therapy.* 2010; 23:230-242.
11. Slots J, Rams TE, Listgarten MA. Yeasts, enteric rods and pseudomonads in the subgingival flora of severe adult periodontitis. *Oral Microbiol Immunol.* 1988; 3(2):47-52.
12. Abu-elteen KH, Abu-elteen RM. The prevalence of *Candida albicans* populations in the mouths of complete denture wearers. *New Microbiol.* 1998; 21(1):41-8.
13. Arendorf TM, Walker DM. The prevalence and intra-oral distribution of *Candida albicans* in man. *Arch Oral Biol.* 1980; (25):1-10.
14. Darwazeh AM, AL-Bashir A. Oral candidal flora in healthy infants. *J Oral Pathol Med.* 1995; 24(8):361-4.
15. Lynch, D.P. Oral candidiasis. History, classification and clinical presentation. *Oral Surg Oral Med Oral Pathol.* 1994; 78(2):189-93.
16. Samaranayake YH, Samaranayake L.P. Experimental oral candidiasis in animal models. *Clin Microbiol Rev.* 2001;14(2): 398-429.
17. Picciani BLS, Michalski-santos B, Carneiro S, *et al.* Oral candidiasis in patients with psoriasis: Correlation of oral examination and cytopathological evaluation with psoriasis disease severity and treatment. *J Am Acad Dermatol.* 2013; 68(6):986-91.
18. Sandrin R, Campagnoli EB, França BHS, *et al.* Comparação entre a citologia em base líquida e a citologia esfoliativa convencional no diagnóstico da candidose bucal. *Rev Odontol UNESP, Araraquara.* 2010; 39(1): 33-39.
19. Scalercio M, Valente T, Israel MS, *et al.* Estomatite protética versus candidíase: diagnóstico e tratamento. *RGO, Porto Alegre.* 2007; 55(4):395-398.
20. Lopez C, Bulacio L, Espejo T, *et al.* Prevalence of chronic hyperplastic candidiasis. Its Association to risk factors in an Oral Medicine Service In Rosario, Argentina. *Journal de Mycologie Médicale.* 2002; 22:35-41.
21. Neville BW, Damm DD, Allen CM, Bouquot JE. *Patologia Oral e Maxilo-facial.* 3a ed. Rio de Janeiro: Elsevier, 2009.
22. Armstrong AW, Bukhalo M, Blauvelt A. A Clinician's Guide to the Diagnosis and Treatment of Candidiasis in Patients with Psoriasis. *Am J Clin Dermatol.* 2016; 17:329-336.
23. Bernstein ML, Miller RL. Oral exfoliative cytology. *J Am Dent Assoc.* Chicago.1978; 96(4):625-629.
24. Davies AN, Brailsford SR, Beighton D, *et al.* Oral Candidosis in Community-Based Patients with Advanced Cancer. *J Pain Symptom Manage.* 2008; 35(5):508-514

Mini Curriculum and Author's Contribution

1. Nathália de Almeida Freire - DDS; MSc. Contribution: effective scientific and intellectual participation for the study; data acquisition, data interpretation; preparation and draft of the manuscript; critical review and final approval. ORCID: 0000-0002-3053-0665
2. Juliana Tristão Werneck - DDS; PhD. Contribution: effective scientific and intellectual participation for the study; data acquisition, data interpretation; preparation and draft of the manuscript; critical review and final approval. ORCID: 0000-0002-9828-0850
3. Eliane Pedra Dias - MD; PhD. Contribution: effective scientific and intellectual participation for the study; data acquisition, data interpretation; preparation and draft of the manuscript; critical review and final approval. ORCID: 0000-0002-0917-6091
4. Adrianna Milagres - DDS; PhD. Contribution: effective scientific and intellectual participation for the study; data acquisition, data interpretation; preparation and draft of the manuscript; critical review and final approval. ORCID: 0000-0001-7324-3183
5. Arley Silva Júnior - DDS; PhD. Contribution: effective scientific and intellectual participation for the study; data acquisition, data interpretation; preparation and draft of the manuscript; critical review and final approval. ORCID: 0000-0003-1839-2789

Submitted: 06/06/2019 / Accepted for publication: 11/12/2019

Corresponding Author

Nathália de Almeida Freire

E-mail: nathaliaafreire@gmail.com